



PANORAMIC Imaging News

Volume 3, Issue 3

US \$6.00

Editor:

Allan G. Farman, BDS, PhD (odont.), DSc (odont.), Diplomate of the American Board of Oral and Maxillofacial Radiology, Professor of Radiology and Imaging Sciences, Department of Surgical and Hospital Dentistry, The University of Louisville School of Dentistry, Louisville, KY.

Featured Article:

Panoramic radiologic appraisal of anomalies of the dentition: Chapter #3 – Tooth morphology

In The Recent Literature:

Film selection

Third molars

Supernumerary teeth

Jaw cysts

Dental age assessment

Stylohyoid ossification

Learning Objectives:

Gain understanding of detection of developmental anomalies of the dentition.

Be able to identify radiographically the following anomalies: dilaceration, taurodontism, enamel pearl, connotation, conrescence, talon cusp, dens invaginatus, dens evaginatus, and supernumerary roots.

Provided as a professional service by:



Panoramic Corporation

In conjunction with

The Richmond Institute
for Continuing Dental Education

A division of Young Innovations, Inc.

Panoramic radiologic appraisal of anomalies of the dentition: Chapter #3 – Tooth morphology

By Dr. Allan G. Farman

The previous chapters reviewed the sequential nature of developmental anomalies of the dentition in general and anomalies in number and size of teeth in particular. This chapter continues the theme of developmental anomalies of the dentition with primary focus on tooth morphology. While coronal anomalies in morphology are most frequently detected without the use of radiographs, anomalies in root morphology are usually not apparent without the assistance of radiology. These conditions can be frequently encountered in the average private general practice and do affect dental treatment planning. For this reason, less attention will be made to anomalies in morphology of tooth crowns, especially for conditions affecting the anterior teeth.

Dilaceration

Dilaceration is an angulation in the root or crown (1,2). The determined prevalence of dilac-

eration depends largely on the subjective assessment of what is "normal" and what is "excessive" angulation. All tooth roots are curved to some degree, so the term dilaceration is reserved for instances of excess or abnormal root curvature that may complicate endodontic or exodontic treatment (Fig. 1). The configuration of the root of a prospective abutment tooth has a significant influence on its potential load-bearing capacity; hence, this abnormality may also affect the stability and longevity of an abutment (2). Dilaceration is most common in the permanent dentition. It is thought to result from prior local infection, trauma or impaction; however, the precise cause has not been elucidated. Clinically, the tooth often appears structurally and positionally normal so the condition is most likely to be discovered radiographically.

It should be remembered that conventional radiographs, including panoramic images, are essentially two-dimensional

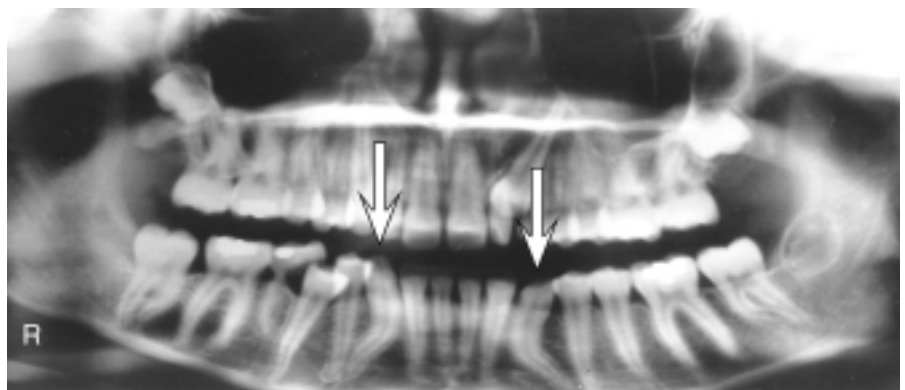


Fig. 1: Bilateral dilacerations of mandibular canines was only evident on radiography. This would need to be considered should orthodontic, endodontic, exodontic or fixed prosthodontic treatment involve these teeth in the future.

“Taurodontism is usually bilateral and symmetric in distribution, although involvement of an isolated tooth is not rare.”

shadows of three-dimensional objects. While mesio-distal dilacerations are relatively easy to determine, bucco-lingual angulations require a little more attention to detail. With dilacerations in a buccal-lingual direction, the radiographic appearance is that of a “bull’s eye” root (Fig. 2) caused by a view down the root axis showing the innermost pulp canal surrounded by tooth structure (1). Missing these forms of dilacerations has been postulated to be a significant factor in the failure of endodontic treatment due to miscalculation of the actual root apex (3).

Taurodontism

Taurodontism is an inherited morphologic anomaly of multirooted teeth caused by failure of invagination of the Hertwig epithelial root sheath (1). Taurodontism is usually bilateral and symmetric in distribution, although involvement of an isolated tooth is not rare. Clinical examination of involved teeth fails to reveal any abnormality. Radiologically, affected molar or premolar teeth appear rectangular with an absence of the normal cervical constriction of the root. There is an increased occlusal-apical dimension to the pulp chamber with diminished apical root length (Fig. 3 and 4).

Taurodontism has been reported in association with a number of conditions (4-8); and is frequently seen in patients having excessive numbers of X chromosomes (9,10). However, it can occur in otherwise normal patients, perhaps as an atavistic memory of prehistoric ancestors. As will be found in most standard texts, the

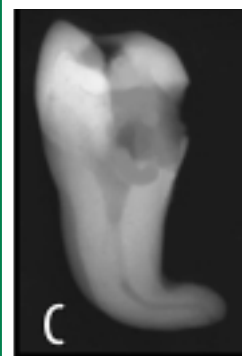
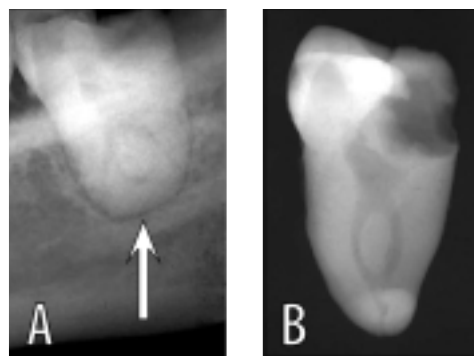


Fig. 2: Bucco-lingual dilacerations need careful radiographic scrutiny for the “bull’s eye” sign shown in the pre-extraction radiographic detail (A). Radiographs of the extracted tooth are

shown in a similar orientation to the pre-extraction radiograph (B) and rotated through 90° (C).

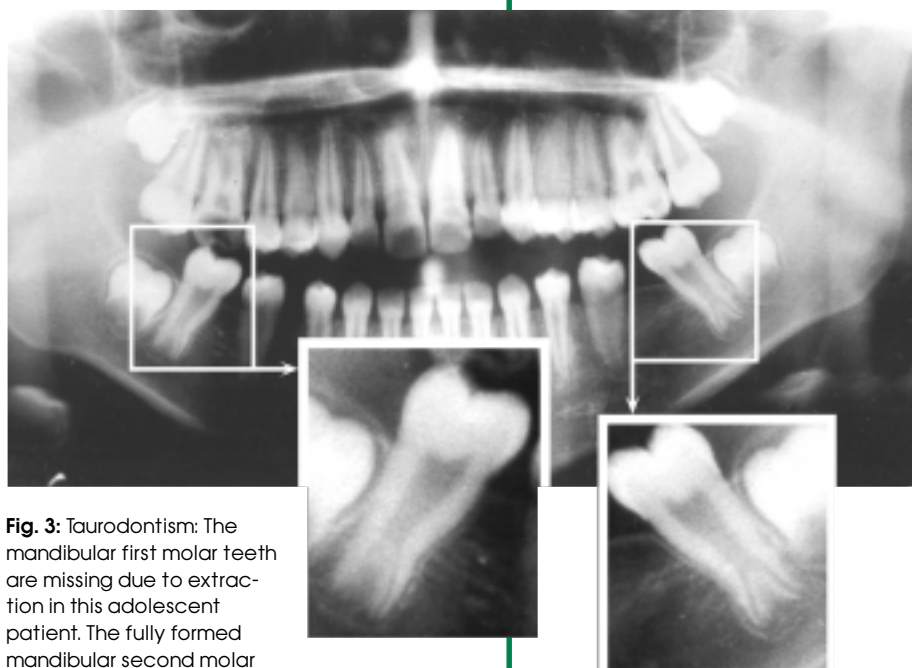

Fig. 3: Taurodontism: The mandibular first molar teeth are missing due to extraction in this adolescent patient. The fully formed mandibular second molar teeth show the typical features of taurodontism; namely an extended pulp chamber and very short apical roots.

condition has been reported in Neanderthal remains found in various sites in Europe (11-12).

Neanderthals are known to exhibit enlarged pulp chambers in postcanine teeth (taurodontism); however, Bailey (2002) found that they are not only unique in their pattern of dental trait frequen-

cies, but also present a high rate of a mid-trigonid crest in lower molars (12). Taurodontism is, however, relatively common in modern man, particularly in Africa (13,14). Toure et al (2000) reported a frequency of 48 % in 150 consecutive Senegalese dental patients

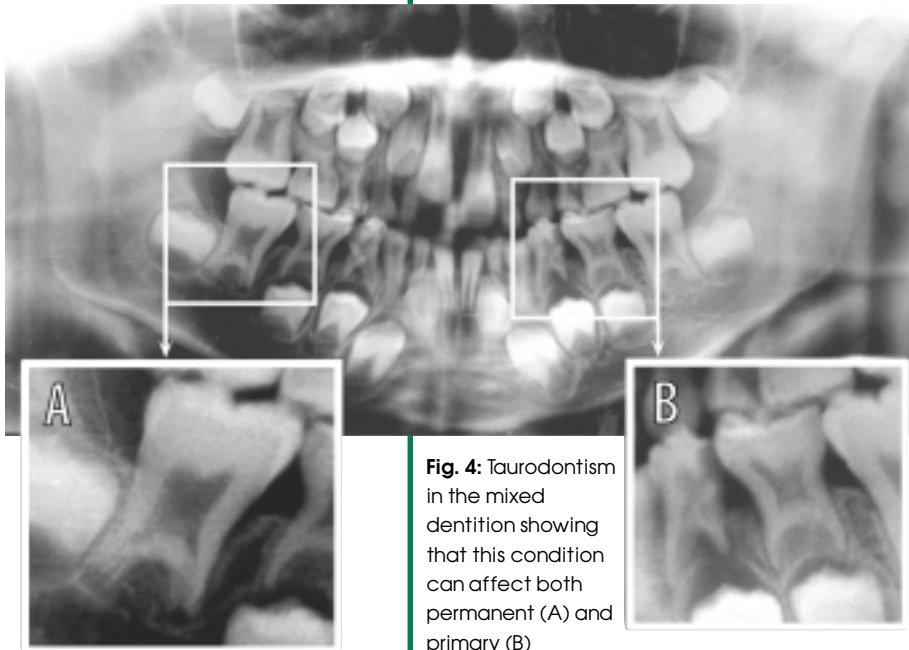


Fig. 4: Taurodontism in the mixed dentition showing that this condition can affect both permanent (A) and primary (B) dentitions.

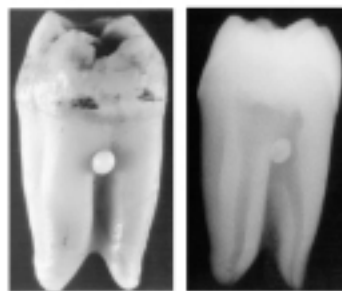
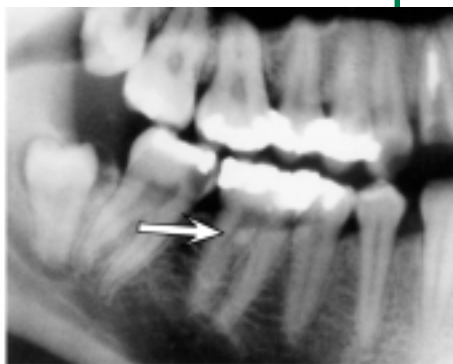


Fig. 5: Enamel pearl shown (arrow) on the detail of a panoramic radiograph. The clinical appearance of enamel pearl on an extracted molar tooth and the radiograph of this extracted tooth are also illustrated.

aged 15-19 years with 18.8% of first and second molars being affected (13). By way of comparison, the prevalence of taurodontism in Jordanians was determined to be 8%, and 11% in a Saudi population (15,16). MacDonald-Jankowski and Li found taurodontism in

56% of female and 36% of male Chinese adolescents who they studied (17). Hence, in diverse populations, taurodontism can be considered simply a variation of normal.

What are the implications of taurodontism for dental treatment? Successful endodontic

therapy has been documented in such teeth (18). It has also been reported that taurodonts show increased susceptibility to apical root resorption during orthodontic treatment (19). Panoramic radiography has been found to be a reliable means of assessing taurodontism (20).

Enamel Pearl

The most common site for extradental enamel pearls is at the cemento-enamel junction of multi-rooted teeth (1). They are most commonly mesial or distal on maxillary teeth and buccal or lingual on mandibular teeth (Fig. 5). Enamel pearls most often occur singly and may be composed exclusively of enamel. They vary in size from microscopic to a few millimeters. Radiologically, they are depicted as dense, smooth radiopacities overlying any portion of the crown or root of an otherwise unaffected tooth. The major radiologic differential diagnosis is projection geometry causing overlap of root contours in multi-rooted teeth. In the primary dentition, radiographic interpretation and detection of the enamel pearl may be complicated by the superimposition of the developing permanent tooth (21). In a study of dental patients, the frequency reported for enamel pearls on molar teeth was 1.6% (22). It has been reported that enamel pearls can predispose to local periodontal disease and should therefore be removed (23); however, as they can contain dentin and pulp, caution is advised.

Connation

Connated or "double" teeth includes both fusion and germination. In the case of fusion of adja-

cent teeth, there should be a reduction in the total number so long as one of the fused teeth is not a supernumerary. In the case of germination, there may be the clinical appearance of an added tooth. The result, in either case, is a tooth with an unusually broad crown that may show grooving between elements that are connected by enamel, dentin, pulp or a combination of these tissues. Connation is comparatively rare depending on the population, being found in from 0.08% of Saudi children to 1.5% of patients examined in western India (24-27). Unless there is failure in eruption, connation is often obvious upon clinical inspection (Fig. 6). Clinical problems relating to fusion may be unacceptable appearance, misalignment of teeth and often periodontal conditions (28).

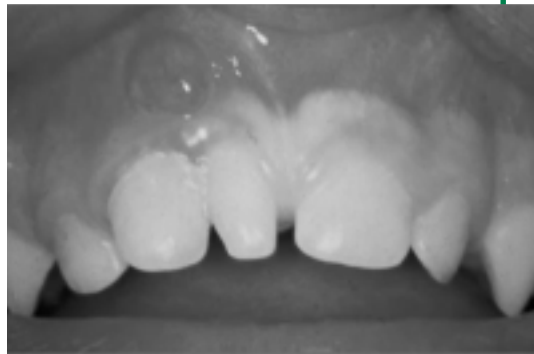
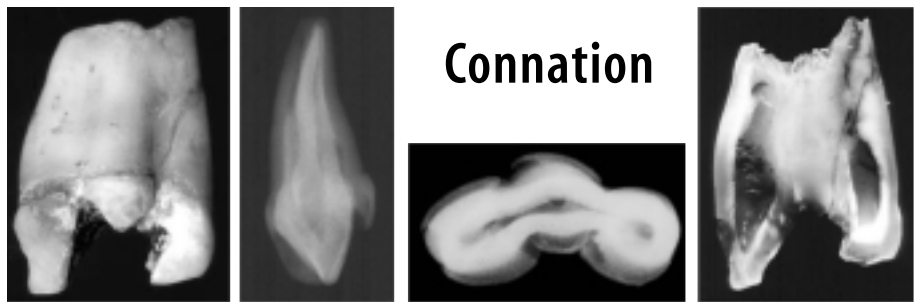


Fig. 6: The upper clinical picture shows a case of connation (germination) of a maxillary central incisor complicated by periodontal disease and lateral periodontal abscess. The lower image sequence is of a connation specimen where a mesiodens is fused to two primary central incisors.



Concrecence

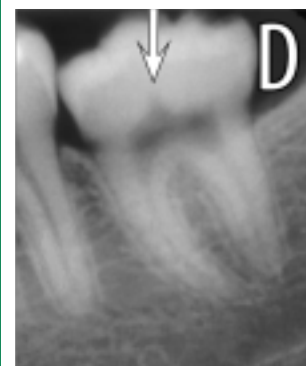
Concrecence is the joining of adjacent teeth through cemental union of their roots (1). It can either occur during development or be acquired. The cardinal radiologic sign of concrecence is close proximity of adjacent teeth with no detectable intervening periodontal ligament space shadow. When developmental, it might be associated with failed eruption of one or more teeth. When acquired, it may be associated with gross hypercementosis.

Talon Cusp

A tooth with a talon cusp generally appears T-shaped (Fig. 7A) when viewed from the incisal edge (1) with most additional cusps being lingual and only rare reports of facial talons (29,30). This condition is clinically obvious and

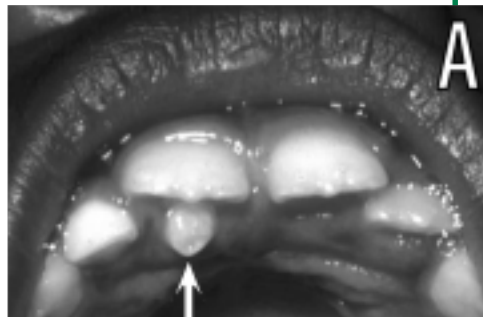

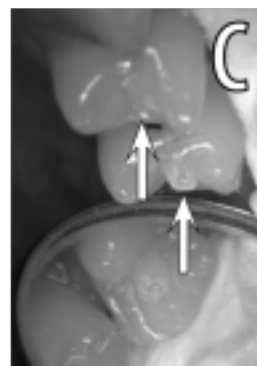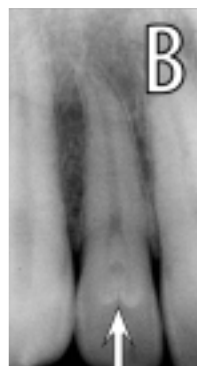Fig. 7A: Talon cusp; **7B:** Dens invaginatus; **7C:** Clinical appearance of dens invaginatus; **7D:** Radiographic detail of dens evaginatus - note how the pulp extends into the central tubercle.



“Dens invaginatus (dens in dente) refers to invagination of tooth structure, most commonly affecting the cingular surface of a maxillary incisor tooth.”

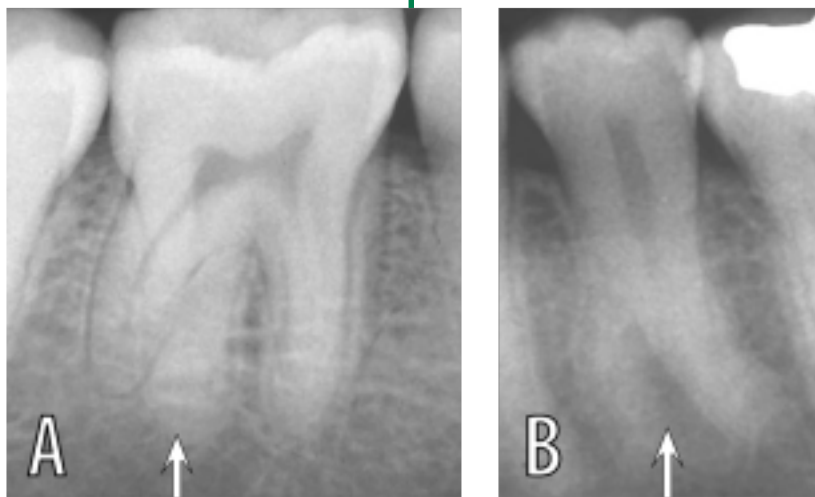


Fig. 8A: Supernumerary root (arrow) on mandibular molar tooth; **8B:** Supernumerary root (arrow) on mandibular premolar tooth.

only requires radiographic analysis to determine whether pulpal extensions may be present within the “talon.” This is best performed using periapical radiography.

Dens Invaginatus

Dens invaginatus (dens in dente) refers to invagination of tooth structure, most commonly affecting the cingular surface of a maxillary incisor tooth (Fig. 7B). This is often, but not invariably, suspected clinically. The lesion needs radiographic appraisal, principally using an intraoral radiograph. If no entrance to the invagination can be detected clinically and there are no signs of pulp pathosis, then no treatment is required other than fissure sealing of the invagination (31,32). In deep invaginations, it is likely that root-canal treatment may be required. Extensive enamel invaginations may be apparent on panoramic

radiographs, as will complication sequels such as an apical abscess, cyst or granuloma.

Dens Evaginatus

Dens evaginatus (Fig. 7C,D) is uncommon in most populations, but occurs in roughly 2% of Asians and Native Americans (33). In this dental anomaly, an extra cusp or tubercle protrudes from the occlusal surface of posterior teeth, or occasionally, from the lingual surface of anterior teeth (34). Complications can arise if the tubercle is worn, ground, or fractured off, resulting in pulpal exposure and possible loss of vitality of the tooth. Radiographs are important to assess the shape of the pulp chamber should dental restorative procedures be required. Orthodontists, considering premolar extraction cases, should include extraction of the anomalous premolars instead of the normal ones. Radiographic assessment is important in such instances.

Supernumerary Roots

The normal number of roots or root canals can show variations from the expected, making radiographic evaluation especially relevant when planning endodontic therapy or exodontias (35,36). Mandibular molars generally have two roots; however, the detail in Figure 8A shows a mandibular molar with three roots. Similarly, the only premolar to consistently have two separate roots is the maxillary first premolar tooth. Figure 8B shows a mandibular premolar with a supernumerary root.

Panoramic Radiology: an important adjunct in the assessment of dental morphology

Panoramic radiography is an important adjunct to clinical inspection for detection of anomalies in dental morphology. Such findings are important in selecting teeth for extraction when needed for orthodontic reasons. Cholitgul and Drummond (2000) studied the panoramic radiographs of 1,608 children and adolescents from New Zealand and found tooth abnormalities in 21% of these studies. They concluded that panoramic radiography is valuable for detecting or confirming dental abnormalities, and supported recommendations for the use of panoramic radiography to aid in the assessment of dental development (37). Panoramic radiographs are also important in planning dental coronal restorations and endodontic therapy. In future issues, *Panoramic Imaging News* will cover anomalies in tooth structure and dental eruption patterns.

“Supplemental supernumerary premolar teeth can become radiographically apparent at a stage much later than that for the regular dentition.”

References

- Farman AG, Nortjé CJ, Wood RE. **Oral and Maxillofacial Diagnostic Imaging**. St. Louis: Mosby 1993;pp.65-104.
- Celik E, Aydinlik E. Effect of a dilacerated root on stress distribution to the tooth and supporting tissues. **J Prosthet Dent** 1991;**65**:771-777.
- Chohayeb AA. Dilaceration of permanent upper lateral incisors: frequency, direction, and endodontic treatment implications. **Oral Surg Oral Med Oral Pathol** 1983;**55**:519-520.
- Seow WK, Needleman HL, Holm IA. Effect of familial hypophosphatemic rickets on dental development: a controlled, longitudinal study. **Pediatr Dent** 1995;**17**:346-350.
- Kaste SC, Hopkins KP, Jones D, Crom D, Greenwald CA, Santana VM. Dental abnormalities in children treated for acute lymphoblastic leukemia. **Leukemia** 1997;**11**:792-796.
- Rajic Z, Mestrovic SR. Taurodontism in Down's syndrome. **Coll Antropol** 1998;**22** Suppl:63-67.
- Melnick M, Shields ED, El-Kafrawy AH. Tricho-dento-osseous syndrome: a scanning electron microscopic analysis. **Clin Genet** 1977;**12**:17-27.
- Aldred MJ, Savarirayan R, Lamande SR, Crawford PJ. Clinical and radiographic features of a family with autosomal dominant amelogenesis imperfecta with taurodontism. **Oral Dis** 2002;**8**:62-68.
- Varella J, Alvesalo L, Mayhall J. Taurodontism in 45,X females. **J Dent Res** 1990 ; **69**:494-495.
- Hillebrand U, Mohr C, Plewa G. Taurodontism in patients with sex chromosome anomalies. **Dtsch Z Mund Kiefer Gesichtschir** 1990;**14**:187-189.
- Lebel S, Trinkaus E. Middle Pleistocene human remains from the Bau de l'Aubesier. **J Hum Evol** 2002;**43**:659-685.
- Bailey SE. A closer look at Neanderthal postcanine dental morphology: the mandibular dentition. **Anat Rec** 2002;**269**:148-156.
- Toure B, Kane AW, Sarr M, Wone MM, Fall F. Prevalence of taurodontism at the level of the molar in the black Senegalese population 15 to 19 years of age. **Odontostomatol Trop** 2000;**23**:36-39.
- Constant DA, Grine FE. A review of taurodontism with new data on indigenous southern African populations. **Arch Oral Biol** 2001;**46**:1021-1029.
- Darwazeh AM, Hamasha AA, Pillai K. Prevalence of taurodontism in Jordanian dental patients. **Dentomaxillofac Radiol** 1998;**27**:163-165.
- Ruprecht A, Batniji S, el-Newehi E. The incidence of taurodontism in dental patients. **Oral Surg Oral Med Oral Pathol** 1987;**63**:743-747.
- MacDonald-Jankowski DS, Li TT. Taurodontism in a young adult Chinese population. **Dentomaxillofac Radiol** 1993;**22**:140-144.
- Hayashi Y. Endodontic treatment in taurodontism. **J Endod** 1994;**20**:357-358.
- Kjaer I. Morphological characteristics of dentitions developing excessive root resorption during orthodontic treatment. **Eur J Orthod** 1995;**17**:25-34.
- Tulensalo T, Ranta R, Kataja M. Reliability in estimating taurodontism of permanent molars from orthopantomograms. **Community Dent Oral Epidemiol** 1989;**17**:258-262.
- Kupietzky A, Rozenfarb N. Enamel pearls in the primary dentition: report of two cases. **ASDC J Dent Child** 1993;**60**:63-66.
- Darwazeh A, Hamasha AA. Radiographic evidence of enamel pearls in Jordanian dental patients. **Oral Surg Oral Med Oral Pathol Oral Radiol Endod** 2000;**89**:255-258.
- Goldstein AR. Enamel pearls as contributing factor in periodontal breakdown. **J Am Dent Assoc** 1979;**99**:210-211.
- Salem G. Prevalence of selected dental anomalies in Saudi children from Gizan region. **Community Dent Oral Epidemiol** 1989;**17**:162-163.
- Backman B, Wahlin BY. Variations in number and morphology of permanent teeth in 7-year-old Swedish children. **Int J Paediatr Dent** 2001;**11**:11-17.
- Knezevic A, Travan S, Tarle Z, Sutalo J, Jankovic B, Ciglar I. Double tooth. **Coll Antropol** 2002;**26**:667-672.
- Tasa GL, Lukacs JR. The prevalence and expression of primary double teeth in western India. **ASDC J Dent Child** 2001;**68**:196-200.
- Mader CL. Fusion of teeth. **J Am Dent Assoc** 1979;**98**:62-64.
- Nadkarni UM, Munshi A, Damle SG. Unusual presentation of talon cusp: two case reports. **Int J Paediatr Dent** 2002;**12**:332-335.
- McNamara T, Haeussler AM, Keane J. Facial talon cusps. **Int J Paediatr Dent** 1997;**7**:259-262.
- Goncalves A, Goncalves M, Oliveira DP, Goncalves N. Dens invaginatus type III: report of a case and 10-year radiographic follow-up. **Int Endod J** 2002;**35**:873-879.
- Gound TG. Dens invaginatus—a pathway to pulpal pathology: a literature review. **Pract Periodontics Aesthet Dent** 1997;**9**:585-594.
- McCulloch KJ, Mills CM, Greenfield RS, Coil JM. Dens evaginatus from an orthodontic perspective: report of several clinical cases and review of the literature. **Am J Orthod Dentofacial Orthop** 1997;**112**:670-675.
- Stecker S, DiAngelis AJ. Dens evaginatus: a diagnostic and treatment challenge. **J Am Dent Assoc** 2002;**133**:190-193.
- Kannan SK, Suganya, Santharam H. Supernumerary roots. **Indian J Dent Res** 2002;**13**:116-119.
- Morrow JW, Hylin DL. Supernumerary rooted primary central incisors: report of seven cases. **ASDC J Dent Child** 1993;**60**:337-338.
- Cholittgul W, Drummond BK. Jaw and tooth abnormalities detected on panoramic radiographs in New Zealand children aged 10-15 years. **N Z Dent J** 2000;**96**:10-13.

In The Recent Literature:

Film selection: Both Kodak Ektavision and Agfa OrthoLux did well in standard sensitometric tests and in the perceived clarity of image features.

Wakoh M, Nishikawa K, Kobayashi N, Farman AG, Kuroyanagi K. Sensitometric properties of Agfa Dentus OrthoLux, Agfa Dentus ST8G, and Kodak Ektavision panoramic radiographic film. Oral Surg Oral Med Oral Pathol Oral Radiol Endod 2001 Feb;91**(2):244-51. (From the Department of Oral and Maxillofacial Radiology Tokyo Dental Clinic, Japan and the University of Louisville, USA.)**

This study compares the panoramic imaging qualities of Kodak Ektavision, Agfa OrthoLux panoramic radiographic film, and Agfa ST8G films in combination with Kodak versus Agfa intensifying screens. The density response and resolution of panoramic radiographic film/intensifying screen combinations was evaluated by means of Hurter and Driffield curves, modulation transfer function (MTF), and noise-equivalent number of quanta (NEQ). Image clarity of selected anatomical structures was also rated. The ISO speed for the Agfa OrthoLux film/screen combinations was the fastest, and the Kodak Ektavision system was the slowest. The average gradient for the Agfa ST8G system was relatively steep in comparison with those for the other film/screen combinations indicating a narrower

recording latitude. The MTFs for the Kodak Ektavision film (a measure of spatial resolution) were higher than those for the Agfa films, irrespective of the screen combination used. The NEQ for the Agfa ST8G film/screen combinations was lower than that for the other film/screen combinations tested. The NEQ for the Kodak Ektavision film/screen combinations was well within the high-frequency range; whereas Agfa OrthoLux combined with either the Kodak Ektavision imaging screen or the Kodak Lanex Regular imaging screen produced a NEQ similar to that of the Kodak Ektavision film/screen combinations in the low-frequency range. Agfa OrthoLux was perceived to provide clearer images of the selected anatomical details than Agfa ST8G, and the Agfa OrthoLux/Agfa Ortho Regular 400 combination was not significantly different from the Kodak Ektavision/Kodak Lanex Regular combination in terms of perceived image quality. Agfa OrthoLux is an improvement over Agfa ST8G in film speed, spatial resolution, granularity, and perceived diagnostic image quality. The Agfa OrthoLux/Agfa Ortho Regular 400 combination; however, did not exceed the Kodak Ektavision film/Kodak Ektavision imaging screen combination in terms of resolution, granularity, and perceived image quality.

Third molars that appear impacted at age 18 y can often erupt into normal occlusion by age 26 y.
Kruger E, Thomson WM, Konthasinghe P. Third molar outcomes from age 18 to 26: findings from a population-

based New Zealand longitudinal study. Oral Surg Oral Med Oral Pathol Oral Radiol Endod 2001;92:150-155. (From the Department of Oral Health, School of Dentistry, University of Otago, Dunedin, New Zealand.)

This study evaluated the presence and impaction status of third molars in persons at age 18 years, as well as the observed changes in their clinical status between ages 18 and 26 years.

This prospective cohort study was performed on 821 individuals for whom panoramic radiographs were taken at age 18 years. For each tooth, its radiographic impaction status at age 18 years was compared with the clinical status by age 26 years. Of the 2857 third molars assessed at age 18 years, 93 % were followed clinically to age 26 years. Approximately 55 % of the teeth that were not impacted by age 18 had erupted by 26 years. Of the teeth that were impacted by age 18, 34 % had fully erupted by age 26, 31 % had been extracted and 13 % remained unerupted. Of the maxillary teeth that were categorized as "impacted" at age 18 years, 36 % had fully erupted by age 26, whereas 26 % of the mandibular teeth had done so ($P < .01$). Fewer mandibular teeth than maxillary teeth remained unerupted by the time the patient was 26 years old (27 % and 41 %, respectively; $P < .01$), but there was no significant difference between the jaws in the proportion of impacted teeth at age 18 years that had been extracted by age 26 years (both 30 %). For mesioangularly impacted third molars, 39 % of maxillary teeth and 20 % of mandibular teeth had fully erupted by age 26, whereas almost one-third of each had been extracted. Of the distoangularly impacted third molars, 20 % of the maxillary

teeth and one-third of the mandibular teeth had erupted by age 26, with 22.6% of the maxillary teeth and 32 % of the mandibular teeth having been extracted. It is concluded that other than horizontally impacted third molars, a substantial proportion of other impaction types do erupt fully, and radiographically apparent impaction in late adolescence should not be sufficient grounds for their prophylactic removal in the absence of other clinical indications.

Supernumerary teeth: Sequential panoramic radiographs evidenced the late development of a post-dentition supplemental supernumerary tooth.

Gibson N. A late developing mandibular premolar supernumerary tooth. Aust Dent J 2001 Mar;46(1):51-2. (From the Torbay Hospital, Torquay, UK.)

Supplemental supernumerary premolar teeth can become radiographically apparent at a stage much later than that for the regular dentition. The case of a patient who developed a mandibular premolar supernumerary tooth between the age of 11 and 20 years is reported. Evidence for the late development of the supernumerary tooth came from consecutive panoramic radiographs.

Jaw cysts: Panoramic images were used to compare the radiographic features of the mandibular odontogenic keratocysts and the dentigerous cysts associated with third molars.

Tsukamoto G, Sasaki A, Akiyama T, Ishikawa T, Kishimura K, Nishiyama A, Matsumura T. A radiologic analysis of dentigerous cysts and odontogenic keratocysts associated with a mandibular third molar. Oral Surg Oral Med Oral Pathol Oral Radiol Endod 2001 Jun;91(6):743-47. (From

the Department of Oral and Maxillofacial Surgery II, Okayama University Dental School, Okayama, Japan.)

The objective was to discriminate radiographically between dentigerous cysts and odontogenic keratocysts associated with a mandibular third molar. Panoramic radiographs were studied for cases of dentigerous cysts (44 patients, 45 cysts) and odontogenic keratocysts (15 patients, 16 cysts). All cysts were associated with a mandibular third molar. The panoramic images were analyzed with reference to the patients' ages and symptoms. The mean age of patients in whom odontogenic keratocysts were detected was less than that of patients having dentigerous cysts. The mean size of odontogenic keratocysts was larger than that of dentigerous cysts. The mean distance from the second to the third molar for dentigerous cysts was greater than that for odontogenic keratocysts. While there was a significant correlation between the lesion size and the distance between the second and third molars in the dentigerous cyst versus the odontogenic keratocyst, the patients' ages did not significantly correlate with these features: Odontogenic keratocysts tended to grow more rapidly than dentigerous cysts, but did not cause as much tooth displacement. No evidence was found for either cyst type to develop gradually from the time of initiation of the dental follicle or the dental lamina. They rather arose randomly at various stages.

Dental age assessment: Panoramic radiography provides an excellent means of assessing the

Provided as a professional service by:



Panoramic Corporation
4321 goshen road, fort wayne, in 46818 • 800.654.2027

dental age of patients; however, there is a need to develop separate assessment standards for different population groups. Davidson LE, Rodd HD. Interrelationship between dental age and chronological age in Somali children. Community Dent Health 2001;18:27-30. (From the Department of Child Dental Health, School of Clinical Dentistry, University of Sheffield, UK).

This cross-sectional study compared dental age with chronological age in Somali children under 16 years of age and age- and gender-matched white Caucasian children, all resident in Sheffield, England. The sample group comprised 162 subjects: 84 Somali and Caucasian boys (mean age 10.6 y) and 78 Somali and Caucasian girls (mean age 11.2 y). The dental age was assessed for each subject, using their existing panoramic radiographs. Comparisons of the difference between dental age and chronological age were made for each gender and both ethnic groups. Independent sample tests were employed for statistical analysis. The level of significance was set at $p < 0.05$. The mean difference between dental age and chronological age was found to be 1.0 years for Somali boys, 0.2 years for Caucasian boys, 1.2 years for Somali girls, and 0.5 years for Caucasian girls. The difference between dental and chronological age was significantly greater in Somali subjects than in Caucasian children. The authors conclude that Somali children are more dentally advanced than their Caucasian peers. This finding underlines the need for population-specific dental development

standards for accurate dental age assessment.

Stylohyoid ossification: Ossification within the stylohyoid chain is demonstrable on panoramic radiography. Such ossification increases with increased patient age.

Krennmair G, Lenglinger F, Lugmayr H. Variants of ossification of the stylohyoid chain. Rof Fortschr Geb Rontgenstr Neuen Bildgeb Verfah 2001 Mar;173(3):200-4. (From the Clinic for Oral and Maxillofacial Surgery, University of Vienna, Austria.)

Panoramic radiographs of 380 patients (including 718 radiographs clearly depicting the regions of the stylohyoid chains), were subdivided into 4 age groups (= 20 y, 21-40 y, 41-60 y, > 60 y), and were reviewed and examined for the incidence, length and location(s) of ossifications in the stylohyoid chains. Elongation of the styloid process and/or ossification of the stylohyoid ligament was found in 221 (30.8%) of the reviewed stylohyoid chains. With increasing age, there was an increase in the prevalence and length of stylohyoid ossifications ($p < 0.01$). A significant linear correlation between the length of the stylohyoid ossifications and age was only found in the young age group (= 20 y; $p < 0.01$). In this age group, there was also a predominance of isolated locations of ossification in the superior stylohyoid segment. With increasing patient age, the presence of ossifications in the middle and inferior stylohyoid segments and combinations of ossified variabilities were prominent. The authors conclude that stylohyoid ossification shows age-related differences in incidence, length and topography.

In conjunction with
The Richmond Institute
for Continuing Dental Education
A division of Young Innovations, Inc.

©2003 Panoramic Corporation (7-03)

PANORAMIC *Imaging* News

Volume 3, Issue 3

CE TEST: Panoramic radiologic appraisal of anomalies of the dentition: Chapter #3 — Tooth morphology

NOTE: These questions are based **both** on the lead article and the abstracts from the recent literature.

1. Taurodontism can be found in almost half of certain normal populations from Africa.
 True False
2. The "bull's eye" radiographic sign is classically found for which of the following?
 a. Conrescence
 b. Dilaceration
 c. Taurodontism
 d. Dens evaginatus
3. Dens evaginatus is found in roughly what percentage of Native Americans?
 a. 0.02
 b. 0.20
 c. 2.00
 d. 20.0
4. Teeth that are connated may be either fused or germinated.
 True False
5. Cholitgul and Drummond did not support the use of panoramic radiography to aid in the assessment of dental development.
 True False
6. Panoramic radiography is important in the detection and diagnosis of talon cusps.
 True False
7. For maxillary molars, the enamel pearl is most frequently found on the mesial or distal surface.
 True False
8. Taurodonts are associated with short pulp chambers and elongated apical root canals.
 True False
9. Third molars that appear impacted on panoramic radiographs at age 18 years should invariably be extracted as they are very unlikely to erupt normally.
 True False
10. Stylohyoid ossification shows age-related differences in incidence, length and topography.
 True False

How to Obtain CE Credit: _____

Successful completion entitles respondent to 1 hour Continuing Education Credit from The Richmond Institute for Continuing Dental Education.

1. Complete questions and required personal information. Name: _____
2. RENTAL CUSTOMERS:
CE fee is included in rental cost. Simply FAX completed form to (847) 458-0063 . Do not send payment. Address: _____
City: _____ State: _____ Zip: _____
3. ALL OTHERS:
A. Mail completed form with \$10 processing fee to
Panoramic Corporation, 2260 Wendt St., Algonquin, IL 60102 Telephone: _____ Date: _____
Mail or FAX completed form with credit card information to (847) 458-0063 Email: _____
B. Make checks payable to Richmond Institute. Credit Card Number: _____ Expiration Date: _____
For \$10 Processing Fee: _____

Signature

Sponsored by:



Panoramic Corporation
4321 goshen road, fort wayne, in 46818 • 800.654.2027

In conjunction with
The Richmond Institute
for Continuing Dental Education
A division of Young Innovations, Inc.