



# PANORAMIC *Imaging* News

Volume 2, Issue 2

US \$6.00

## Editor:

Allan G. Farman, BDS, PhD  
(odont.), DSc (odont.),  
Diplomate of the  
American Board of Oral  
and Maxillofacial  
Radiology, Professor of  
Radiology and Imaging  
Sciences, Department of  
Surgical and Hospital  
Dentistry, The University of  
Louisville School of  
Dentistry, Louisville, KY.

## Contributor:

Dr. C.J. Nortjé, BChD, PhD, DSc,  
Professor and Chairman of  
Oral and Maxillofacial  
Radiology, Tygerberg, South  
Africa, President-Elect of the  
International Association of  
Dentomaxillofacial Radiology.

## Featured Article:

Panoramic radiographic  
appearance of the  
mandibular canal in health  
and in disease

## Panoramic radiographic appearance of the mandibular canal in health and in disease

**By Dr. Allan G. Farman in  
collaboration with Dr. C.J. Nortjé**

The mandibular canal is of particular importance to the dentist and dental specialist as it carries both the dental division of the trigeminal nerve and the innervation for the lower lip. The trigeminal nerve enters the inner surface of the mandibular ramus at the mandibular foramen, in the vicinity of a bony eminence, the lingula. This is a fact learned in study of anatomy and reinforced by the everyday necessity of locating an inferior dental block injection for local analgesia required in many dental procedures. What is not so well understood is that normal is a range and that variations do occur in which there may be more than one nerve entry point - a factor that might account for failed anesthesia in at least a small percentage of patients. Such variations have been described both during studies of macerated mandibles from cadavers and also from the study of panoramic radiographs. Panoramic radiographs may also help find the position of the mental foramen, through which the nerve supply to the lower lip passes. Failure to protect the mental foramen can lead to permanent loss of normal sensation in the lower lip. The panoramic radiographic positioning of the mental foramen and the mandibular canal has been used as an indication of bone loss following dental extractions.

A comprehensive study of variations in the mandibular canal in patients who had not suffered mandibular pathoses or trauma

found that the mandibular canals are usually, but not invariably, bilaterally symmetrical, and that the majority of hemimandibles contain only one major canal.<sup>1</sup> The position of the canal varies with respect to the apices of the tooth roots and the lower border of the mandible. They can be classified as high (Type I - close to the apices of the teeth), intermediate (Type II) or low (Type III - close to the lower cortex of the mandible) varieties.<sup>2</sup> The proportions of types varies with the investigation perhaps indicating a geographic or ethnic variability.<sup>1,2</sup> Neither study showed a gender difference with respect to the positioning of the canal. There were almost equal numbers of high and low canals in a South African study with few intermediate canals.<sup>1</sup> In a Greek study there were few high canals and almost equal proportions of intermediate and low canals.<sup>2</sup> The Greek study also found asymmetry in canal positioning in almost one in five of those studies; whereas the South African study found this to occur in less than one in a hundred.<sup>1,2</sup> It can be concluded that in a single panoramic radiograph the mandibular canal should not be used as a set reference point for assessment of bone loss following extractions. To make such an assessment requires sequential panoramic radiographs on a given patient.

Supplemental mandibular canals large enough to be seen on panoramic radiography are rare but are occasionally present, the most common being duplicate canals commencing from a single mandibular foramen, and the least

Provided as a professional service by:



**Panoramic Corporation**

in conjunction with The Richmond Institute  
for Continuing Dental Education

*“Primary lesions developing within the mandibular canal are frequently neural or vascular in origin.”*

common arising from two separate foramina (Fig. 1 & 2).<sup>1-3</sup> Such duplicate canals are found in only 0.5 to 1.0 % of studied adult populations.<sup>1,2,4</sup> They are sometimes termed “bifid canals.”<sup>2,4</sup> That such bilateral canals are a reality rather than a projection artifact has been proven both by anatomical dissection (Carter and Keen 1971)<sup>5</sup> and also by computed tomography (Quattrone et al. 1989)<sup>6</sup>. Whether the contents are neural, neurovascular or simply vascular is a contentious point. If nerves were present in the two canals, this might account for some failure to achieve local anesthesia when applying block injections.

On occasion, appearance of duplicated mental foramina is also observed (Fig. 3). Such true duplication needs to be distinguished from the separate depictions of the mental canal at its origin from the mandibular canal central within bone, and at its exit from the facial cortex of the mandible.

It is possible that bifid canals represent a minor expression of structural twinning. Very rarely, the mandible may evidence agnathus, a variant of paragnathus.<sup>7</sup> Such a case, subsequently treated successfully by surgeons Davis and Breytenbach in Cape Town, South Africa, is illustrated in Fig. 4. In this case, unilateral duplication of the mandible was accompanied by duplication of the mandibular canal - and also of the dentition for that jaw quadrant.

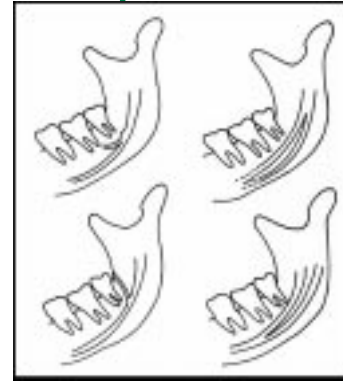
### **Pathological conditions of the mandible**

The effects of pathological conditions of the mandible on the panoramic appearance of the mandibular canal was first reported by the author of the present report,

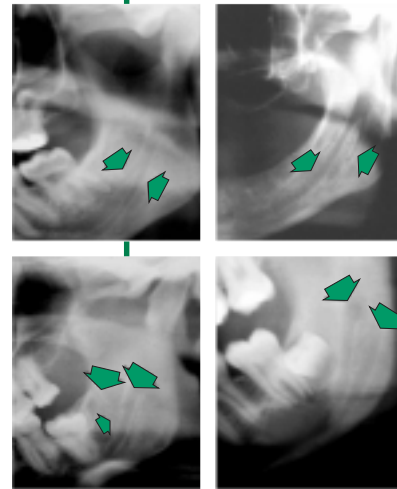
a quarter of a century ago.<sup>8</sup> It was found that various disease processes can affect the panoramic radiographic appearance of the mandibular canal in a variety of ways. Localized loss of the canal cortical bone was found with chronic apical periodontitis, chronic pericoronitis, advanced chronic destructive periodontitis (in patients having a high mandibular canal), and rarely also with very large Stafne’s bone cavities. Generalized loss of the canal’s cortical bone was usually indicative of severe infection or aggressive neoplasia, and was found in association with rarefying osteomyelitis, invasive squamous cell carcinoma, multiple myeloma, osteogenic sarcoma and occasionally with ameloblastoma. Displacement of the canal suggested a benign cystic or neoplastic process, and was found with large radicular cysts, residual dental cysts, dentigerous cysts and the cemento-ossifying fibroma among other benign conditions.

### **Benign lesions within the mandibular canal**

Primary lesions developing within the mandibular canal are frequently neural or vascular in origin. Benign neoplasm within the canal will tend to widen the canal and cause superior and inferior displacement of the canal as the lesion expands. Especially with slow growing

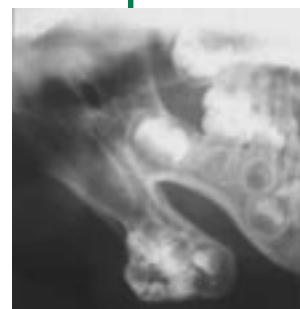
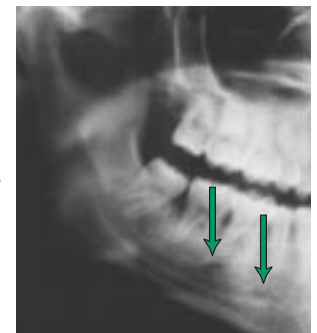
**Fig. 1.** Examples of “bifid,” or “duplicate,” mandibular canals. Such canals have been confirmed in various studies both using anatomical dissection and by computed tomography.



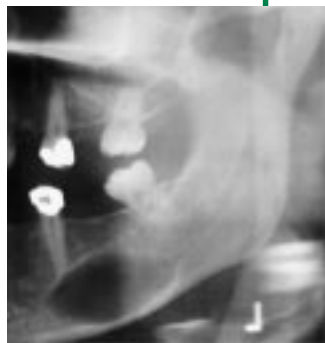**Fig. 2.** Details from panoramic radiographs demonstrating various “duplicate,” or “bifid” mandibular canals.

**Fig. 3.** Duplicated mental foramen (detail from panoramic radiograph).

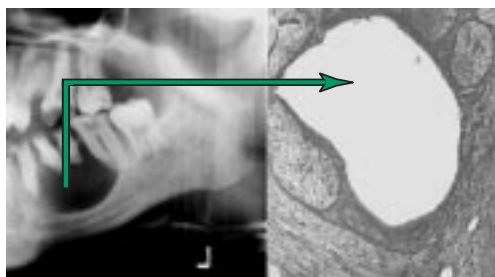
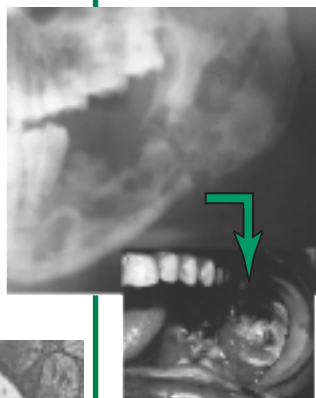

**Fig. 4.** Agnathus (a variant of paragnathus) demonstrating an extreme form of duplication of the mandibular canal. (Case treated by Professors D. Davis and M. Breytenbach, Cape Town, South Africa.)

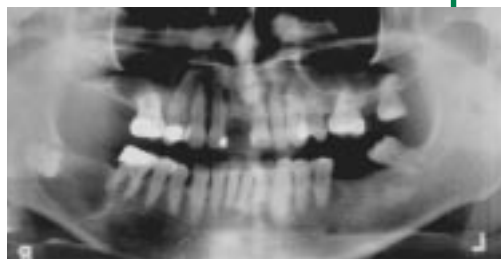**Fig. 5.** Neurilemmoma within mandibular canal. The canal is greatly dilated by this homogeneously radiolucent benign neoplasm.



**Fig. 6.** Leiomyosarcoma (malignant neoplasm of smooth muscle), epicentered on the mandibular canal, with destruction of the canal's cortical outlines.



**Fig. 7.** Radicular cyst arising from the grossly decayed left mandibular first permanent molar tooth. Pressure developing within the cyst due to an osmotic gradient causes growth of the lesion and displacement of adjacent structures including the mandibular canal.



**Fig. 8.** Large dentigerous cyst associated with the crown of a horizontally positioned unerupted third molar tooth in the right side of the mandible. The right mandibular canal is displaced downwards in comparison with the ipsilateral canal.

lesions the cortical plate of the canal will remain intact. Fig. 5 illustrates a case of neurilemmoma arising within the mandibular canal. This is a homogeneously radiolucent lesion that has caused dilation of the canal in the site of the tumor. The normal canal blends with the lesion both mesially and distally with the cortical plate expanding to encompass the lesion. Certainly, not all neurilemmomas of the mandible are associated with dilation of the mandibular canal, especially if they are situated in the premolar or anterior regions.<sup>10</sup> However, dilation of the mandibular canal, when present, does suggest a lesion epicenter within the canal.

Shapiro et al (1984) investigated the maxillofacial radiographic manifestations of neurofibromatosis (von Recklinghausen's disease), a condition affecting one in 3000 live births in which those affected are prone to the development of benign neural tumors, neurofibromas.<sup>11</sup> They found that 72 % of the 22 subjects studied had oral or maxillofacial radiological signs of the disease such as widened mandibular canals (6 cases) or enlarged mandibular foramina (6 cases including two who also had widened canals). Lee et al. (1996) found that six of 10 patients with neurofibromatosis showed enlargement of the mandibular foramen.<sup>12</sup>

### **Malignant lesions within the mandibular canal**

Primary malignancies arising within the mandibular canal are extremely rare.<sup>13</sup> When they do arise they will reflect a tissue of origin from the site concerned; i.e. neural, vascular, fibrous or smooth muscle. Fig. 6 illustrates a case of primary leiomyosarcoma arising in the left mandibular body and causing destruction of the canal outline. The

**Fig. 9.** Ameloblastoma in the right mandibular body. The lesion resulted in resorption of the apices of the superjacent teeth - but in downward displacement of the intact subjacent mandibular canal.



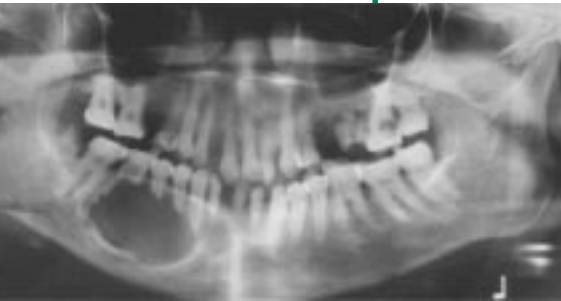**Fig. 10.** Cementoblastoma of the mandibular first permanent molar tooth displacing the roots of the second premolar and permanent second molar teeth. The mandibular canal has also been displaced downwards.

**Fig. 11.** Cementoblastoma of the mandibular first permanent molar tooth displacing the roots of the second premolar and permanent second molar teeth. The mandibular canal has also been displaced downwards.

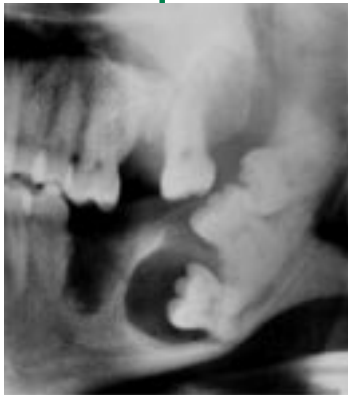**Fig. 12.** Squamous cell carcinoma invading the left mandibular body and ramus - and eroding the mandibular canal cortices. The lesion originated peripherally to bone and hence is "saucer-shaped."



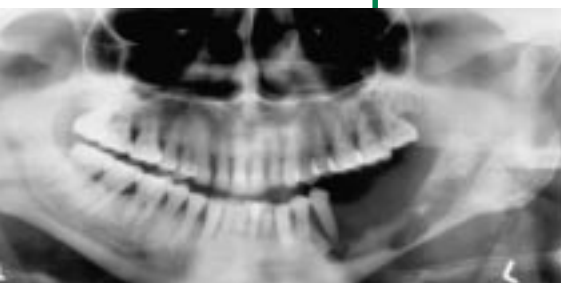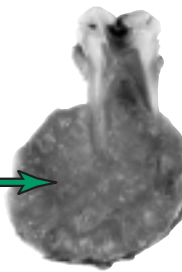
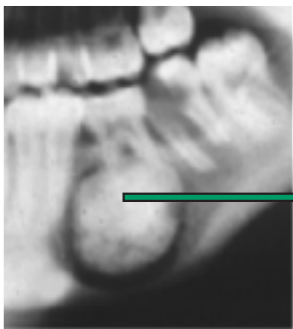
*“Slow growing benign cysts and tumors peripheral to the mandibular canal are likely to cause gradual displacement of the canal rather than resorption of the canal cortices.”*



calcifying epithelial  
genetic tumor causing  
and displacement of  
mandibular first  
molar which  
development of the  
y a radiolucency  
ling a dentigerous  
mandibular canal is  
d towards the lower  
f the mandible.



ma  
d  
ent  
he



young male patient evidenced paresthesia of the left side of the lower lip. No other site of disease was found so this is presumed a primary lesion. Not all malignancies cause destruction of the canal outline. Extranodal non-Hodgkin's lymphoma has been reported to cause enlargement of the canal not unlike that described for benign tumors.<sup>14,15</sup> Metastases affecting the mandibular canal site are also rare, but certainly more common than primary malignancies.

### **Benign lesions peripheral to the mandibular canal**

Slow growing benign cysts and tumors peripheral to the mandibular canal are likely to cause gradual displacement of the canal rather than resorption of the canal cortices. Examples of such conditions are illustrated in Fig. 7-11. When a homogeneous radiolucency is associated with expansion of the apical periodontal ligament space of a non-vital root canal, and the lesion is large enough to cause displacement of the mandibular canal, the most likely diagnosis is a radicular cyst (Fig. 7.). If a homogeneous radiolucency surrounds the crown of an unerupted tooth and is attached to the tooth at the enamel-cemental junction. The most likely diagnosis is a dentigerous cyst. It should be cautioned that a variety of other conditions can envelope the crown of a tooth; hence, histopathological confirmation is required. Large dentigerous cysts can also cause the displacement of the affected tooth and if it approaches the mandibular canal displacement, is to be

expected (Fig. 8.). Benign tumors can also cause canal displacement. The most common benign odontogenic neoplasm is the ameloblastoma (Fig. 9.) and this can either cause displacement or resorption of the canal, or can in some cases simply camouflage the canal by addition of septae and "soap bubble" trabecular patterns. Fig. 10 is a detail from a panoramic radiograph of a patient having a calcifying epithelial odontogenic tumor. The lesion has displaced an adjacent tooth and there is dilatation or invasion of the follicle space resembling a dentigerous cyst. This highlights the importance of histopathological evaluation of tissue from supposed dentigerous cysts. The displaced tooth has also resulted in displacement of the mandibular canal in this case.

Fig. 11 illustrates the detail of a cementoblastoma that has displaced the mandibular canal towards the lower cortex of the mandible. The features of this condition are entirely benign.<sup>16</sup> While this particular case was excised in its entirety, it is sometimes possible to endodontically treat an affected tooth and then simply surgically excise the lesion.

### **Malignant lesions peripheral to the mandibular canal**

Severe infections, such as suppurative osteomyelitis, and malignant neoplasms are not infrequently associated with an irregular erosion or lysis of the affected jaw - and the mandibular canal is not spared in this process.

The most common

*“A study of gingival carcinoma found no statistical difference between the diagnostic accuracy of panoramic radiographs and computed tomography for the determination of the supero-inferior invasion of the mandible.”*

malignancy affecting the oral cavity is squamous cell carcinoma arising in the oral mucosa. The lesion can secondarily invade adjacent bone (Fig. 12). Lesions arising within bone generally have a “brandy glass” appearance when they erode outwards. In comparison, lesions arising peripherally, such as invading squamous cell carcinoma, produce a “saucerized” appearance. The mandibular canal might be thought of as a “highway for metastases” hence, erosion of this structure can be viewed as a negative factor regarding prognosis. A study of gingival carcinoma found no statistical difference between the diagnostic accuracy of panoramic radiographs and computed tomography for the determination of the supero-inferior invasion of the mandible.<sup>17</sup>

The most common malignancy of bone is myeloma. This condition tends to occur in late middle age and in the elderly with “punched-out” radiolucencies often being found in many bones, but showing a particular predilection to the calvarium. An example of a lytic lesion forming centrally within the mandible is illustrated in Fig. 13. This particular lesion has not spared the mandibular canal and has resulted in a pathological fracture.

Less common malignancies of the jaws include the osteogenic sarcoma and the chondrosarcoma. Both of these conditions cause lysis of normal bone, including the cortices of the mandibular canal when the lower jaw is affected. Both can also demonstrate abnormal bone formation including floccules or “sunburst” appearances. A “sunburst” appearance is demonstrated in the osteogenic

sarcoma illustrated in Fig. 14 where trabeculations of abnormal new bone are superimposed on the basic lytic lesion. This case also demonstrates a “floating tooth” where the bone supporting a left mandibular molar has been destroyed and growth of the lesion has elevated the tooth.

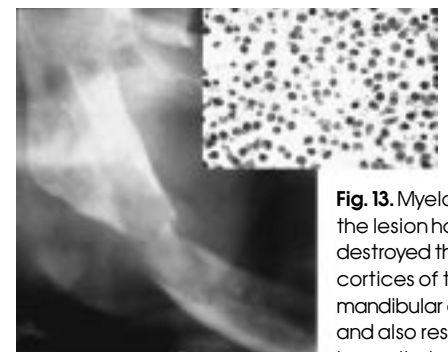
### **Lesions obscuring the mandibular canal**

Some conditions can obscure the appearance of the mandibular canal through producing a complex trabecular pattern that camouflages the canal. Conditions that cause this effect include benign tumors such as the odontogenic myxoma, hamartomas such as intraosseous hemangiomas, and the familial “fibro-osseous” condition, cherubism (Fig. 15.) Cherubism is a dominantly inherited condition that is usually bilateral and predominantly affects both sides of the mandible. Other conditions that may obscure the mandibular canal are those in which dense bone is deposited. Such conditions include osteopetrosis, late stage fibrous dysplasia (Fig. 16.) and florid osseous dysplasia (Fig. 17.) Fibrous dysplasia generally arises in young individuals and causes expansion of the jaw unilaterally and typically does not cross the midline. Sclerosis generally occurs by early adulthood. Florid osseous dysplasia most frequently is found in middle age women of African extraction.

### **Concluding Remarks**

It is sometimes believed that the special anatomic structures of the jaws - especially the teeth - make the radiologic interpretation of disease entities affecting the jawbones particularly difficult as they hinder comparison with

lesions of a similar nature found in bones elsewhere in the body.<sup>18</sup> The converse can be the case if the affects on these very structures are used as clues to discovering the nature of the condition. The mandibular canal is usually clearly depicted in the panoramic dental radiograph. The dentist's familiarity with the normal range for its anatomy - and the ways in which it can be affected by various disease entities, should place the dentist at an advantage in detection and interpretation of the normal, versus disease. It should be kept in mind that while some disease entities produce consistent features that might help radiologic differentiation, others (e.g. ameloblastoma) show variable or non-specific changes. Nevertheless, in combination with the other well-described radiologic features of these lesions, interpretation of changes concerning the canal as shown on panoramic radiography may well assist in deriving a more accurate differential diagnosis list. In particular, canal displacement is almost invariably a feature of benign lesions, whereas extensive loss of the canal cortical plate is usually a feature of severe infection or aggressive neoplasia.

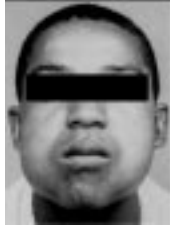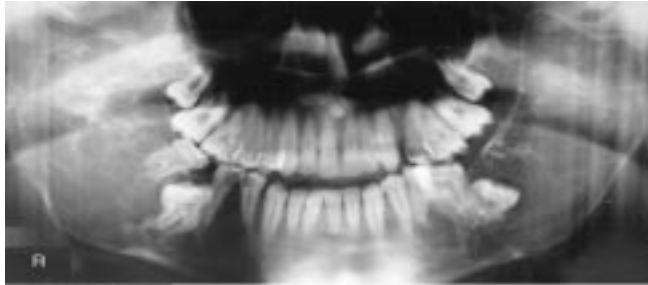


**Fig. 13.** Myeloma: the lesion has destroyed the cortices of the mandibular canal and also resulted in a pathological fracture of the jaw.

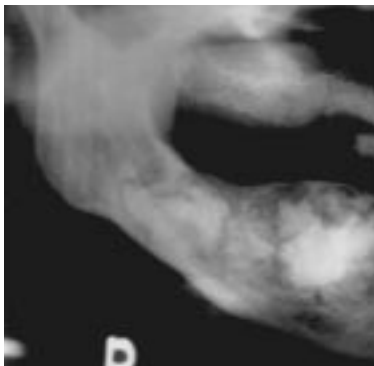
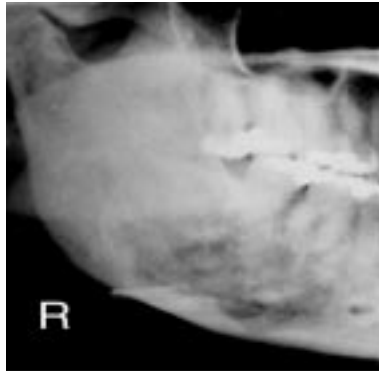


**Fig. 14.** Osteogenic sarcoma of the left mandible. The lytic phase of the lesion has destroyed the outline of the mandibular canal. Note the "sunburst" appearance of new bone formation that is considered a classic, but not invariable, feature of the condition.

**Fig. 15.** Cherubism: The trabecular patterns within the bilateral lesions of the mandible obscure the outlines of the mandibular canals in the affected areas.



**Fig. 16.** Fibrous dysplasia (late phase): The "frosted glass" trabeculations that develop in the latter stages of fibrous dysplasia have reduced the clarity of the mandibular canal.



**Fig. 17.** While most lesions of florid osseous dysplasia occur above the mandibular canal, large lesions combined with factors of panoramic projection geometry conspire to obscure the mandibular canals.

## References

1. Nortjé CJ, Farman AG, Grotepass FW. Variations in the normal anatomy of the inferior dental (mandibular) canal: a retrospective study of panoramic radiographs from 3612 routine dental patients. *Brit J Oral Surg* 1977; 15:55-63.
2. Zografos J, Kolokoudias M, Papadakis E. Types of the mandibular canal. *Hell Period Stomat Gnathopathoprosopike Cheir* 1990;5:17-20.
3. Nortjé CJ, Farman AG, Joubert JJ de V. Radiographic appearance of the inferior dental canal: additional variation. *Brit J Oral Surg* 1977;15:171-172.
4. Langlais RP, Broadus R, Glass BJ. Bifid mandibular canals in panoramic radiographs. *J Am Dent Assoc* 1985;110:923-926.
5. Carter RB, Keen EN. The intramandibular course of the inferior alveolar canal. *J Anat* 1971;108:433-440.
6. Quattrone G, Furloni E, Bianciotti M. Bilateral bifid mandibular canal, presentation of a case. *Minerva Stomatol* 1989;38:1183-1185.
7. Farman AG, Escobar V. Duplication of the oral and maxillofacial structures. *Quintessence* 1986;17:731-737.
8. Farman AG, Nortjé CJ, Grotepass FW. Pathological conditions of the mandible: their effect on the radiographic appearance of the inferior dental (mandibular) canal. *Brit J Oral Surg* 1977;15:64-74.
9. Xie Q, Wolf J, Tilvis R, Ainamo A. Resorption of the mandibular canal wall in edentulous aged population. *J Prosthet Dent* 1997;77:596-600.
10. Nakasato T, Katoh K, Ehara S, Tamakawa Y, Hoshino M, Izumizawa M, Sakamaki K, Fukuta Y, Kudoh K. Intraosseous neuilemmoma of the mandible. *AJNR Am J Neuroradiol* 2000;21:1945-1947.
11. Shapiro SD, Abramovitch K, Van Dis ML, Skoczylas LJ, Langlais RP, Jorgenson RJ, Young RS, Riccardi VM. Neurofibromatosis: oral and radiographic manifestations. *Oral Surg Oral Med Oral Pathol* 1984;58:493-498.
12. Lee L, Yan YH, Pharoah MJ. Radiographic features of the mandible in neurofibromatosis: a report of 10 cases and review of the literature. *Oral Surg Oral Med Oral Pathol Oral Radiol Endod* 1996;81:361-367.
13. Farman AG, Kay S. Leiomyosarcoma of the oral cavity. *Oral Surg* 1977;43:402-409.
14. Yamada T, Kitagawa Y, Ogasawara T, Yamamoto S, Ishii Y, Urasaki Y. Enlargement of mandibular canal without hypesthesia caused by extranodal non-Hodgkin's lymphoma. *Oral Surg Oral Med Oral Pathol Oral Radiol Endod* 2000;89:388-392.
15. Bertolotto M, Cecchini G, Martinoli C, Perrone R, Garlaschi G. Primary lymphoma of the mandible with diffuse widening of the mandibular canal. *Eur Radiol* 1996;6: 637-639.
16. Farman AG, Köhler WW, Nortjé CJ, van Wyk CW. Cementoblastoma. *J Oral Surg* 1979; 37:198-203.
17. Nakayama E, Yoshiura K, Yuasa K, Tabata O, Araki K, Kanda S, Ozeki S, Shinohara M. Detection of bone invasion by gingival carcinoma of the mandible: a comparison of intraoral and panoramic radiography and computed tomography. *Dentomaxillofac Radiol* 1999;28:351-356.

Provided as a professional service by:



**Panoramic Corporation**

4321 goshen road, fort wayne, in 46818 • 800.654.2027

in conjunction with The Richmond Institute for Continuing Dental Education

©2002 Panoramic Corporation (04-02)

